

Immunoglobulin G4 related disease: an overview

Saika Farook^{1*}, Abdullah Ahmed Solaiman², Md. Shariful Alam Jilani³

¹Department of Microbiology, Molecular and Flow Cytometry, DMFR Molecular Lab & Diagnostics BD LTD, Dhaka, Bangladesh, ²Department of Surgery, Metropolitan Hospital, Dhaka, Bangladesh, ³Department of Microbiology, Ibrahim Medical College, Dhaka, Bangladesh

Abstract

Immunoglobulin G4 related disease (IgG4-RD) is a recently perceived fibroinflammatory condition, identified as a systemic illness for the first time in the early 2000. It can involve virtually every organ of the body, commonly presenting as lymphadenopathy, retroperitoneal fibrosis, autoimmune pancreatitis, tubulointerstitial nephritis, parotid or lacrimal gland enlargement. The diagnosis is confirmed by histopathological analysis and is often, but not always accompanied by an increased level of serum IgG4 concentration. In fact, the name addressing this autoimmune fibroinflammatory condition may be considered a misnomer, as the role of the non-inflammatory immunoglobulin IgG4 in the immune mechanism of IgG4-RD remains to be elucidated.

IMC J Med Sci 2021; 15(2): 006. DOI: <https://doi.org/10.3329/imcjms.v15i2.55878>

Introduction

IgG4-RD is a chronic immune mediated fibroinflammatory condition appertaining to tumefactive lesions that can involve any anatomic site of the body. The underlying pathogenesis of this rare disease relies on the expansion of a unique type of CD4 positive cytotoxic T cells, which exert cytolytic effect on the target tissue, rather than IgG4 dependant cytotoxicity as the name implies. The disease can be identified by distinctive histological features such as presence of lymphoplasmacytic infiltrate, storiform fibrosis, obliterative phlebitis, and a high proportion of IgG4-expressing plasmablasts or plasma cells in affected tissues [1,2]. Previously considered unrelated, IgG4-related disease unifies numerous well-known illnesses, namely Mikulicz's disease (affecting the salivary and lacrimal glands), Riedel's thyroiditis, Morbus Ormond (retroperitoneal fibrosis), Kuttner's tumor (affecting submandibular glands), multifocal fibrosclerosis and other entities [3]. Owing to the heterogeneity of clinical features and radiological findings, diagnosis is often difficult and delayed, thus heavily relying on histopathological analysis.

An International symposium held in 2011 provided a set of guidelines for the diagnosis of IgG4-RD. Even the nomenclature of this newly discovered condition continues to evolve and the term IgG4-related disease has recently been elected in preference to alternatives such as IgG4-related systemic disease, IgG4-related sclerosing disease, and IgG4-related multi-organ lymphoproliferative syndrome [4].

Epidemiology

The global epidemiology of the disease is not well defined as of yet owing to under-recognition. Most of the studies related to IgG4-RD are from Japan and are focused on autoimmune pancreatitis, as 20-25% of IgG4-RD is associated with pancreatic involvement [5]. A study conducted in 2011 estimated the incidence of IgG4-RD in Japan to be 0.28-1.08/100,000 population, with 336-1,300 newly diagnosed patients each year [6]. Moreover, the prevalence of autoimmune pancreatitis rose from 2.2/100 000 in 2007 to 4.6/100 000 in 2011 in the country, which was definitely due to increased recognition of the disease [5]. About two-third of

*Correspondence: Saika Farook, Department of Microbiology, Molecular and Flow Cytometry, DMFR Molecular Lab & Diagnostics BD LTD, Dhaka, Bangladesh. Email: sairana15@yahoo.com

the patients affected are men with a median age of 58 years [7]. Although IgG4-RD is not commonly found in children, but a recent review has described 25 cases of children with the condition; 11 of these children were suffering from orbital disease while three had autoimmune pancreatitis [8].

Immunopathology

Since the establishment of the disease entity, several studies have been conducted to elucidate the immunopathogenesis of IgG4-RD. The immunoglobulin IgG4 has restricted ability to bind complement and to interact with activating Fc receptors for which it is considered as a non-inflammatory immunoglobulin [9]. Hence, whether IgG4 play an active role in the autoimmune mechanism of the disease is still questionable.

A study conducted by Zhang et al. (2015) has demonstrated that the IgG subclass of autoantibodies, IgG1 and IgG3, that are produced in response to protein autoantigens are elevated in autoimmune diseases such as primary Sjogren syndrome (pSS), primary biliary cirrhosis, systemic lupus erythematosus (SLE) and systemic sclerosis, whereas IgG2, produced in response to carbohydrate autoantigens, are reduced in such diseases [10]. However, it is extremely difficult to differentiate between IgG4-RD with other autoimmune disorders based on the serum concentration of the subclass IgG4, as IgG4 concentration may be increased in various clinical conditions other than IgG4-RD [11]. As for instance, whereas one study reported increased serum IgG4 level in 7.5% patients with pSS together with diagnostic features of IgG4-RD; another study found only 2.94% pSS patients with raised IgG4 levels and without features of IgG4-RD [10, 12]. Consequently, the role of IgG4 in the pathogenesis of IgG4-RD, its role as a diagnostic biomarker and even the naming of the condition as "IgG4-RD" is perplexing and controversial and further clinical research is required to establish its involvement in the disease.

Recent studies claim, interactions among clonally expanded CD4+ cytotoxic T-lymphocytes (CD4+CTL), T follicular helper (TFH) cells, and B cells play a major role in the immunopathogenesis of

IgG4-RD [13]. Annexin A11 and galactin-3 have been implicated to be the causative autoantigens [14]. The plasmablasts or activated B cells in patients with IgG4-RD are specific for these autoantigens and are oligoclonally restricted, resulting in clonal expansion of CD4+ CTL in tissue sites [13]. CD4+ CTLs are a unique CD4+ T cells with cytolytic capabilities, especially found associated with chronic viral infections and malignancies [15]. In IgG4-RD, CD4+ CTLs in affected tissues, secrete profibrotic cytokines including interleukin (IL)-1 β , transforming growth factor β 1 (TGF- β 1), and interferon γ (IFN- γ) as well as cytolytic molecules such as perforin and granzymes A and B, responsible for killing target cells. Furthermore, IL-4-secreting TFH cells are also expanded in blood and tissue sites, which are essentially responsible for germinal center formation, affinity maturation, class switching to IgG isotypes including IgG4 and the development of most high affinity memory B cells [13, 16].

Risk factors

Several immune mediated mechanisms are thought to play a role in the fibroinflammatory process of IgG4-RD. Since the condition is relatively new, these factors are not well established and further extensive studies are essential to confirm their contributions.

Genetic factors: Genetic studies revealed that the HLA serotypes DRB1*0405 and DQB1*0401 are associated with increased susceptibility to IgG4-related disease in Japanese populations, whereas DQB1-57 without aspartic acid is related to disease relapse in Korean populations [17, 18].

Bacterial infection and molecular mimicry: The human carbonic anhydrase II enzyme bears homologous segments with α -carbonic anhydrase of *Helicobacter pylori*, which serves as the binding site for the DRB1*0405 molecule [19]. Additionally, pancreatic acinar cells consist of ubiquitin-protein ligase E3 component n-recogin 2 which are also homologous to the plasminogen-binding protein of *H. pylori* [20]. A study conducted with a single patient of IgG4-RD revealed that peripheral blood mononuclear cells produced IgG4 and IL-10, in

response to stimulation with toll-like receptor ligands, suggesting that different species of bacteria may induce the immune mechanism of IgG4 RD [21]. However, further extensive research is required to confirm this results.

Autoimmunity: Autoimmunity is regarded as one of the most influential factors that trigger the T-cell immune response in IgG4-RD. Previous studies claimed that potential autoantigens, located at the epithelial cells of the pancreatic ducts, bile ducts, and salivary-gland ducts, include carbonic anhydrases, lactoferrin, pancreatic secretory trypsin inhibitor, and trypsinogens [22-24]. However, autoantibodies directed against such antigens are neither specific for IgG4-RD nor known to be of the IgG4 subclass [23]. On the contrary, Annexin A11 is a novel autoantigen recently discovered to be targeted by IgG4 and IgG1 antibodies in serum of patients with IgG4-RD of the biliary tract, pancreas and salivary glands [14]. Another study conducted in 2018 revealed that Galectin-3 was identified as the antigen specifically recognized by plasmablasts. Anti-galectin-3 autoantibody responses are predominantly of the IgG4 isotype [25].

Clinical Features

IgG4-RD can affect any organ of the body and can present with varied clinical features. Presentation is usually subacute; fever and elevation of C-reactive protein levels are unusual. The disorder is often diagnosed incidentally through radiologic findings or unpredictably in pathological specimens [26]. However, patients with multi-organ involvement may suffer from weight loss - about 9 to 14 kgs over a period of few weeks to months before reaching the correct diagnosis [26].

Tumefactive lesions and allergic disease are two usual findings in IgG4-RD. Patients with IgG4-RD often present with subacute development of tumorous swellings in different organ systems [27-29]. A lot of patients may have allergic features such as atopy, eczema, asthma, and modest peripheral blood eosinophilia, whereas up to 40% of patients with IgG4-RD have allergic diseases such as bronchial asthma or chronic sinusitis [30]. Untreated IgG4-related cholangitis may lead to

hepatic failure within months [31]. Around 10 - 50% cases of inflammatory aortitis is thought to be associated with IgG4-related aortitis, which if left untreated may result in aneurysms and aortic dissections [32, 33]. Similarly, untreated IgG4-related tubulointerstitial nephritis may lead to renal dysfunction and even renal failure [34].

IgG4-RD is relatively new in Bangladesh and cases have not been reported widely. Till now, a single case of IgG4-related peri-aortitis has been reported in 2018, suggesting that although the incidence of the disease exists in Bangladesh, cases are not being unmasked extensively [35]. This is possibly due to a lack of awareness as well as adequate diagnostic facilities. Clinicians should remain concerned to the possibility that IgG4-RD often presents with features of malignancy and may mimic some autoimmune rheumatic diseases such as Sjögren's syndrome, systemic lupus erythematosus (SLE), and granulomatosis with polyangiitis [36].

Diagnosis

Histological analysis of the affected tissue is the cornerstone of definitive disease diagnosis aided by elevated serum IgG4 concentration. However, the serum IgG4 concentration is not a specific diagnostic marker and misdiagnoses of IgG4-related disease are increasingly common as much emphasis is given on elevations of the non-specific, non-inflammatory biomarker IgG4 concentration along with over-dependency on the detection of IgG4-positive plasma cells in the affected tissue [32]. Once a diagnosis has been made, further thorough investigations are required to assess for subclinical or multiple organ involvement as well as symptomatic features such as albuminuria, necessitated for management planning [5].

Histopathological features: The characteristic features of IgG4-related disease are a dense lymphoplasmacytic infiltrate organized in a storiform (matted and irregularly whorled) pattern, obliterative phlebitis, and the presence of mild-to-moderate eosinophil infiltrates [37]. The histologic appearance of IgG4-related disease, though highly characteristic, requires immunohistochemical confirmation with IgG4 immunostaining. In

Bangladesh, IgG4 staining is not commonly done in histopathological laboratories, which may have resulted in missed diagnoses of the disease. IgG4 subclass of immunoglobulin predominates within the involved tissue [32]. Although, diagnosis of IgG4-RD relies substantially on the presence of IgG4-positive plasma cells in the affected tissue, but it is not considered as a definite diagnostic benchmark of the disease, as IgG4-positive cells are also found in a wide variety of inflammatory infiltrates [32]. However, IgG4 positive plasma cells, ranging from more than 10 to 50 per high-power field has been proposed as a diagnostic criterion [38, 39]. It has been suggested that the diagnosis of IgG4-related disease is further assured if the ratio of IgG4-bearing plasma cells to IgG-bearing plasma cells is higher than 50% [32].

Imaging features: The appearance of lesions in images demonstrated either radiologically or by computed tomography (CT-scan) varies considerably, particularly in the lung and kidney [40]. The imaging features are usually nonspecific and cannot particularly distinguish between IgG4-related disease and malignancy.

Serological findings: Most patients with IgG4-RD present with an elevated concentration of serum IgG4 (reference range: 0.03- 2.01 g/L). However, 30% patients with characteristic histopathological features may report a normal serum IgG4 concentration, leading to misdiagnosis [41]. A study exhibited the positive predictive value (PPV) to be below 40% in case of increased serum IgG4 level (upper limit of normal= 1.35 g/L). Four times the upper limit of normal (IgG4 > 5.6 g/L) reveals a PPV of 100% whilst two times the upper limit of normal value reduces the PPV to 28% only, for the diagnosis of IgG4 associated sclerosing cholangitis. Moreover, excessively high concentrations of serum IgG4 level is associated with multiple organ involvement (6.99 g/L) while the average rise in concentration of serum IgG4 is about 2.33 g/L when a single organ is affected [42, 43].

Although IgG4 level reduces in patients whose serum IgG4 concentration was raised at baseline following treatment with glucocorticoids, they may remain above normal values in certain patients [41]. Interestingly, a study conducted in Japan

revealed that IgG4 concentration was not reduced to normal level in 115 out of 182 (63%) patients treated with glucocorticoids [44].

The serum IgE level was found to be elevated in 40% of patients with IgG4-RD [45]. A study by Kanari et al. (2010) with 9 patients of IgG4 related lacrimal gland enlargement demonstrated increased IgE concentrations (>170 IU/ml) in all 9 patients, attributed to the fact that IgG4 is produced as an intermediate product during class switching from IgM to IgE under the influence of the cytokines IL-4 and IL-13 [45-47].

Therefore, the diagnosis of IgG4-RD is determined by the combination of clinical, imaging, serological and histological criteria. A summary diagnostic scheme of IgG4-RD is shown in Figure-1.

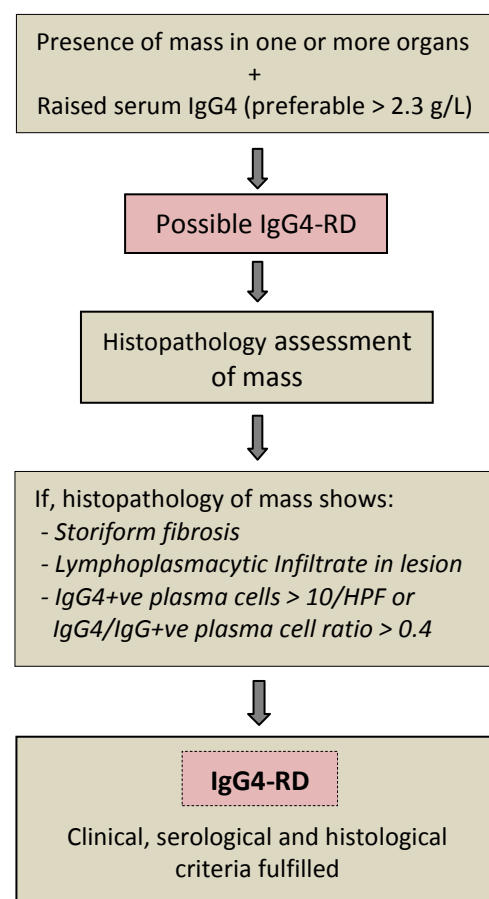


Figure-1: Diagnostic scheme of IgG4-RD. Serum IgG4 - normal up to 1.35 g/L. HPF: high power field (400x); +ve: positive.

Treatment

Glucocorticoids are reportedly the first line of treatment. Patients are typically treated with a starting dose of prednisolone at 0.6 mg per kilogram of body weight for 2 to 4 weeks [48]. It is then tapered over a period of 3 to 6 months to 5.0 mg per day, and then continued at a dose between 2.5 and 5.0 mg per day for up to 3 years. Alternatively, glucocorticoid therapy has been suggested to discontinue entirely within 3 months [44]. Immunosuppressive drugs such as methotrexate, azathioprine, mycophenolate mofetil are additionally used as remission-maintenance drugs, but their efficacy in IgG4-RD has not been tested in clinical trials [32]. However, the long term use of glucocorticoids contributes to certain drawbacks in the management of the usually middle-aged patients, such as a 30-60% relapse rate of IgG4-RD as well as persistent side-effects that includes diabetes mellitus, infections and osteoporotic fractures [49, 50]. Consequently, clinical trials with rituximab, an anti-CD20 monoclonal B-cell depleting antibody, have been reported with promising results [50, 51]. Rituximab was found to be effective as both induction and maintenance therapy for IgG4-RD. A cohort trial conducted with 156 patients nevertheless reported 40% relapse in patients treated with rituximab after 2 years, the reason for which was attributed to baseline high disease activity and the lack of maintenance therapy with rituximab. The trial also reported 11 patients with severe infection as possible side effects of B-cell depletion therapy [52].

Conclusion

IgG4 related disease is still uncommon, and the diagnosis is difficult to establish. At present, the overall incidence, the therapeutic intervention and course of glucocorticoid therapy, the mechanism and risk factors of glucocorticoid resistance, duration of maintenance therapy, the effect of immunosuppressive agents and long-term prognosis, are not very well understood in IgG4-RD. Additionally, in Bangladesh and in other countries the condition is not very well-known or established which probably has resulted in its underdiagnosis. Early diagnosis of the disease and exclusion of differential diagnoses are essentially significant as

appropriate management with glucocorticoids, rituximab or other immunosuppressive agents can result in prompt remission as well as prevention of complications such as multi-organ involvement, fibrosis and renal failure. However, in the absence of definite clinical features, pre-operative diagnosis is still challenging and IgG4-RD may continue as a diagnostic pitfall.

Conflict of interest: None

Reference

1. Mahajan VS, Mattoo H, Deshpande V, Pillai SS, Stone JH. IgG4-related disease. *Annu Rev Pathol.* 2013; **9**: 315–347.
2. Kamisawa T, Zen Y, Pillai SS, Stone JH. IgG4-related disease. *Lancet.* 2015; **385**(9976): 1460–1471.
3. Quattrocchio G, Roccatello D. IgG4-related nephropathy. *J Nephrol.* 2016; **29**(4): 487–93.
4. Umehara H, Okazaki K, Masaki Y, Kawano M, Yamamoto M, Saeki T, et al. A novel clinical entity, IgG4-related disease (IgG4RD): general concept and details. *Mod Rheumatol.* 2012; **22**: 1–14.
5. Chen LY, Mattman A, Seidman MA, Carruthers MN. IgG4-related disease: what a hematologist needs to know. *Haematologica.* 2019; **104**(3): 444–455.
6. Umehara H, Okazaki K, Masaki Y, Kawano M, Yamamoto M, Saeki T, et al. Comprehensive diagnostic criteria for IgG4-related disease (IgG4-RD). *Mod Rheumatol.* 2012; **22**(1): 21–30.
7. Comai G, Cuna V, Fabbri B, Sabatini E, Leone O, Tondolo F, et al. A case report of IgG4-related disease: an insidious path to the diagnosis through kidney, heart and brain. *BMC Nephrol.* 2019; **20**(1): 1–7.
8. Karim F, Loeffen J, Bramer W, Westenberg L, Verdijk R, van Hagen M, et al. IgG4-related disease: a systematic review of this unrecognized disease in pediatrics. *Pediatr Rheumatol.* 2016; **14**(1): 1–9.
9. Bruhns P, Iannascoli B, England P, Mancardi DA, Fernandez N, Jorieu S, et al. Specificity

- and affinity of human Fc gamma receptors and their polymorphic variants for human IgG subclasses. *Blood*. 2009; **113**(16): 3716–25.
10. Zhang H, Li P, Di Wu DX, Hou Y, Wang Q, Li M, et al. Serum IgG subclasses in autoimmune diseases. *Medicine*. 2015; **94**(2): e387.
 11. Yamamoto M, Tabeya T, Naishiro Y, Yajima H, Ishigami K, Shimizu Y, et al. Value of serum IgG4 in the diagnosis of IgG4-related disease and in differentiation from rheumatic diseases and other diseases. *Mod Rheumatol*. 2012; **22**(3): 419-25.
 12. Mavragani CP, Fragoulis GE, Rontogianni D, Kanariou M, Moutsopoulos HM. Elevated IgG4 serum levels among primary Sjogren's Syndrome patients: Do they unmask underlying IgG4-Related disease? *Arthritis Care Res*. 2014; **66**(5): 773-777.
 13. Maehara T, Moriyama M, Nakamura S. Pathogenesis of IgG4-related disease: a critical review. *Odontology*. 2019; **107**(2): 127-32.
 14. Hubers LM, Vos H, Schuurman AR, Erken R, Elferink RPO, Burgering B, et al. Annexin A11 is targeted by IgG4 and IgG1 autoantibodies in IgG4-related disease. *Gut*. 2018; **67**(4): 728-735.
 15. Soghoian DZ, Jessen H, Flanders M, Davidson KS, Cutler S, Pertel T, et al. HIV-specific cytolytic CD4 T cell responses during acute HIV infection predict disease outcome. *Sci Transl Med*. 2012; **4**(123): 123ra25.
 16. Crotty S. Follicular helper CD4 T cells (TFH). *Annu Rev Immunol*. 2011; **29**: 621- 663.
 17. Kawa S, Ota M, Yoshizawa K, Horiuchi A, Hamano H, Oci Y, et al. HLA DRB10405-DQB10401 haplotype is associated with autoimmune pancreatitis in the Japanese population. *Gastroenterology*. 2002; **122**(5): 1264-1269.
 18. Park DH, Kim MH, Oh HB, Kwon OJ, Choi YJ, Lee SS, et al. Substitution of aspartic acid at position 57 of the DQbeta1 affects relapse of autoimmune pancreatitis. *Gastroenterology*. 2008; **134**(2): 440-446.
 19. Guarneri F, Guarneri C, Benvenga S. *Helicobacter pylori* and autoimmune pancreatitis: role of carbonic anhydrase via molecular mimicry? *J Cell Mol Med*. 2005; **9**(3): 741-4.
 20. Frulloni L, Lunardi C, Simone R, Dolcino M, Scattolini C, Falconi M, et al. Identification of a novel antibody associated with autoimmune pancreatitis. *N Engl J Med*. 2009; **361**(22): 2135-42.
 21. Akitake R, Watanabe T, Zaima C, Uza N, Ida H, Tada S, et al. Possible involvement of T helper type 2 responses to Toll-like receptor ligands in IgG4-related sclerosing disease. *Gut*. 2010; **59**(4): 542-5.
 22. Aparisi L, Farre A, Gomez-Cambronero L, Martinez J, Heras GDL, Corts J, et al. Antibodies to carbonic anhydrase and IgG4 levels in idiopathic chronic pancreatitis: relevance for diagnosis of autoimmune pancreatitis. *Gut*. 2005; **54**(5): 703-9.
 23. Asada M, Nishio A, Uchida K, Kido M, Ueno S, Uza N, et al. Identification of a novel autoantibody against pancreatic secretory trypsin inhibitor in patients with autoimmune pancreatitis. *Pancreas*. 2006; **33**(1): 20-6.
 24. Lohr JM, Faissner R, Koczan D, Bewerunge P, Bassi C, Brors B, et al. Autoantibodies against the exocrine pancreas in autoimmune pancreatitis: gene and protein expression profiling and immunoassays identify pancreatic enzymes as a major target of the inflammatory process. *Am J Gastroenterol*. 2010; **105**(9): 2060-71.
 25. Perugino CA, AlSalem SB, Mattoo H, Della-Torre E, Mahajan V, Ganesh G, et al. Identification of galectin-3 as an autoantigen in patients with IgG4-related disease. *J Allergy Clin Immunol*. 2019; **143**(2): 736-45.
 26. Stone JH, Khosroshahi A, Deshpande V, Chan JK, Heathcote JG, Aalberse R, et al. IgG4-related disease: recommendations for the nomenclature of this condition and its individual organ system manifestations. *Arthritis Rheum*. 2012; **64**(10): 3061-7.
 27. Stone JH, Khosroshahi A, Hilgenberg A, Spooner A, Isselbacher EM, Stone JR. IgG4-related systemic disease and

- lymphoplasmacytic aortitis. *Arthritis Rheum.* 2009; **60**(10): 3139-45.
28. Dahlgren M, Khosroshahi A, Nielsen GP, Deshpande V, Stone JH. Riedel's thyroiditis and multifocal fibrosclerosis are part of the IgG4-related systemic disease spectrum. *Arthritis Care Res.* 2010; **62**(9): 1312-8.
 29. Saeki T, Saito A, Hiura T, Yamazaki H, Emura I, Ueno M, et al. Lymphoplasmacytic infiltration of multiple organs with immunoreactivity for IgG4: IgG4-related systemic disease. *Intern Med.* 2006; **45**(3): 163-7.
 30. Kamisawa T, Anjiki H, Egawa N, Kubota N. Allergic manifestations in autoimmune pancreatitis. *Eur J Gastroenterol Hepatol.* 2009; **21**(10): 1136-9.
 31. Bjornsson E. Immunoglobulin G4- associated cholangitis. *Curr Opin Gastroenterol.* 2008; **24**(3): 389-94.
 32. Stone JH, Khosroshahi A, Deshpande V, Stone JR. IgG4-related systemic disease accounts for a significant proportion of thoracic lymphoplasmacytic aortitis cases. *Arthritis Care Res.* 2010; **62**(3): 316-22.
 33. Khosroshahi A, Carruthers M, Deshpande V, Unizony S, Bloch DB, Stone JH. Rituximab for the treatment of IgG4-related disease: lessons from ten consecutive patients. *Medicine.* 2012; **91**(1): 57-66.
 34. Raissian Y, Nasr SH, Larsen CP, Colvin RB, Smyrk TC, Takahashi N, et al. Diagnosis of IgG4-related tubulointerstitial nephritis. *J Am Soc Nephrol.* 2011; **22**(7): 1343-52.
 35. Razzak MA, Alam SZ, Nasrin S, Rahman QA. IgG4 related peri-aortitis: a case diagnosed in Combined Military Hospital, Dhaka. *J. Armed Forces Med Coll.* 2018; **14**(2): 217-9.
 36. Moutsopoulos HM, Fragoulis GE, Stone JH. Pathogenesis and clinical manifestations of IgG4-related disease. *Up To Date.* 2019.
 37. Deshpande V, Gupta R, Sainani NI, Sahani DV, Virk R, Ferrone C, et al. Subclassification of autoimmune pancreatitis: a histologic classification with clinical significance. *Am J Surg Pathol.* 2011; **35**(1): 26-35.
 38. Dhall D, Suriawinata AA, Tang LH, Shia J, Klimstra DS. Use of immunohistochemistry for IgG4 in the distinction of autoimmune pancreatitis from peritumoral pancreatitis. *Hum Pathol.* 2010; **41**(5): 643-52.
 39. Deshpande V, Chicano S, Finkelberg D, Selig MK, Kenudson MM, Bruge WR, et al. Autoimmune pancreatitis: a systemic immune complex mediated disease. *Am J Surg Pathol.* 2006; **30**(12): 1537-45.
 40. Takahashi N, Kawashima A, Fletcher JG, Chari ST. Renal involvement in patients with autoimmune pancreatitis: CT and MR imaging findings. *Radiology.* 2007; **242**(3): 791-801.
 41. Sah RP, Chari ST. Serologic issues in IgG4-related systemic disease and autoimmune pancreatitis. *Curr Opin Rheumatol.* 2011; **23**(1): 108-13.
 42. Boonstra K, Culver EL, de Buy Wenniger LM, van Heerde MJ, van Erpecum KJ, Poen AC, et al. Serum immunoglobulin G4 and immunoglobulin G1 for distinguishing immunoglobulin G4-associated cholangitis from primary sclerosing cholangitis. *Hepatology.* 2014; **59**(5): 1954-63.
 43. Carruthers MN, Khosroshahi A, Augustin T, Deshpande V, Stone JH. The diagnostic utility of serum IgG4 concentrations in IgG4-related disease. *Ann Rheum Dis.* 2015; **74**(1): 14-8.
 44. Kamisawa T, Shimosegawa T, Okazaki K, Nishino T, Watanabe H, Kanno A, et al. Standard steroid treatment for autoimmune pancreatitis. *Gut.* 2009; **58**(11): 1504-7.
 45. Kanari H, Kagami SI, Kashiwakuma D, Oya Y, Furuta S, Ikeda K, et al. Role of Th2 cells in IgG4-related lacrimal gland enlargement. *Int Arch Allergy Immunol.* 2010; **152**(1): 47-53.
 46. Aalberse RC, Stapel SO, Schuurman J, Rispens T. Immunoglobulin G4: an odd antibody. *Clin Exp Allergy.* 2009; **39**(4): 469-77.
 47. Jabara HH, Loh R, Ramesh N, Vercelli D, Geha RS. Sequential switching from mu to epsilon via gamma 4 in human B cells stimulated with IL-4 and hydrocortisone. *J Immunol.* 1993; **151**(9): 4528-33.

48. Kamisawa T, Okazaki K, Kawa S, Shimosegawa T, Tanaka M. Japanese consensus guidelines for management of autoimmune pancreatitis. III. Treatment and prognosis of AIP. *J Gastroenterol*. 2010; **45**(5): 471-7.
49. Ebbo M, Daniel L, Pavic M, Sève P, Hamidou M, Andres E, Burtsey S, et al. IgG4-related systemic disease: features and treatment response in a French cohort: results of a multicenter registry. *Medicine*. 2012; **91**(1): 49-56.
50. Brito-Zerón P, Kostov B, Bosch X, Acar-Denizli N, Ramos-Casals M, Stone JH. Therapeutic approach to IgG4-related disease: a systematic review. *Medicine*. 2016; **95**(26): e4002.
51. Carruthers MN, Topazian MD, Khosroshahi A, Witzig TE, Wallace ZS, Hart PA, et al. Rituximab for IgG4-related disease: a prospective, open-label trial. *Ann Rheum Dis*. 2015; **74**(6):1171-7.
52. Ebbo M, Grados A, Samson M, Groh M, Loundou A, Rigolet A, Terrier B, Guillaud C, Carra-Dallière C, Renou F, Pozdzik A. Long-term efficacy and safety of rituximab in IgG4-related disease: data from a French nationwide study of thirty-three patients. *PLOS One*. 2017; **12**(9): e0183844.